



## CLINICAL REPORT

# Guidance on Management of Asymptomatic Neonates Born to Women With Active Genital Herpes Lesions

David W. Kimberlin, MD, Jill Baley, MD, COMMITTEE ON INFECTIOUS DISEASES, and COMMITTEE ON FETUS AND NEWBORN

**KEY WORDS**

newborn, herpes simplex virus, acyclovir, pregnancy

**ABBREVIATIONS**

CNS—central nervous system

CSF—cerebrospinal fluid

HSV—herpes simplex virus

HSV-1—herpes simplex virus type 1

HSV-2—herpes simplex virus type 2

IgG—immunoglobulin G

PCR—polymerase chain reaction

SEM—skin, eye, mouth

This document is copyrighted and is property of the American Academy of Pediatrics and its Board of Directors. All authors have filed conflict of interest statements with the American Academy of Pediatrics. Any conflicts have been resolved through a process approved by the Board of Directors. The American Academy of Pediatrics has neither solicited nor accepted any commercial involvement in the development of the content of this publication.

The guidance in this report does not indicate an exclusive course of treatment or serve as a standard of medical care. Variations, taking into account individual circumstances, may be appropriate.

**FUNDING:** Funded in whole or in part with Federal funds from the National Institute of Allergy and Infectious Diseases, National Institutes of Health, Department of Health and Human Services, under contract (N01-AI-30025, N01-AI-65306, N01-AI-15113, N01-AI-62554), the General Clinical Research Unit (M01-RR00032), and the State of Alabama. Funded by the National Institutes of Health (NIH).

[www.pediatrics.org/cgi/doi/10.1542/peds.2012-3216](http://www.pediatrics.org/cgi/doi/10.1542/peds.2012-3216)

doi:10.1542/peds.2012-3216

All clinical reports from the American Academy of Pediatrics automatically expire 5 years after publication unless reaffirmed, revised, or retired at or before that time.

PEDIATRICS (ISSN Numbers: Print, 0031-4005; Online, 1098-4275).

Copyright © 2013 by the American Academy of Pediatrics

## abstract



Herpes simplex virus (HSV) infection of the neonate is uncommon, but genital herpes infections in adults are very common. Thus, although treating an infant with neonatal herpes is a relatively rare occurrence, managing infants potentially exposed to HSV at the time of delivery occurs more frequently. The risk of transmitting HSV to an infant during delivery is determined in part by the mother's previous immunity to HSV. Women with primary genital HSV infections who are shedding HSV at delivery are 10 to 30 times more likely to transmit the virus to their newborn infants than are women with recurrent HSV infection who are shedding virus at delivery. With the availability of commercial serological tests that reliably can distinguish type-specific HSV antibodies, it is now possible to determine the type of maternal infection and, thus, further refine management of infants delivered to women who have active genital HSV lesions. The management algorithm presented herein uses both serological and virological studies to determine the risk of HSV transmission to the neonate who is delivered to a mother with active herpetic genital lesions and tailors management accordingly. The algorithm does not address the approach to asymptomatic neonates delivered to women with a history of genital herpes but no active lesions at delivery. *Pediatrics* 2013;131:e635–e646

## INTRODUCTION

Herpes simplex virus (HSV) infection of the neonate is an uncommon occurrence, with an estimated 1500 cases diagnosed annually in the United States from a birth cohort of more than 4 000 000. In contrast, genital herpes infections in adults are very common. Between 1 in 4 and 1 in 5 adults in the United States has genital herpes caused by HSV type 2 (HSV-2).<sup>1,2</sup> In addition, HSV type 1 (HSV-1) now accounts for at least 20% and, in some locales, more than 50% of cases of genital herpes in the United States.<sup>3,4</sup> Therefore, managing infants potentially exposed to HSV at the time of delivery is not uncommon, and prevention of the devastating outcomes of neonatal HSV disease is paramount.

Current recommendations for the management of infants after intrapartum exposure are based on expert opinion, because a randomized controlled trial to determine whether an exposed neonate should be treated would be unethical. However, the existing recommendations do

not take into account recent information correlating risk of transmission with type of maternal infection (primary versus recurrent) at the time of delivery.<sup>5</sup> The algorithm contained within this American Academy of Pediatrics (AAP) clinical report for the diagnostic and therapeutic approach to the neonate with known potential exposure to HSV during the perinatal period incorporates the most current scientific understanding of the biology, epidemiology, and pathology of HSV infection and disease.

### TERMINOLOGY OF HSV INFECTION AND DISEASE

When an individual with no HSV-1 or HSV-2 antibody acquires either virus in the genital tract, a first-episode primary infection results. If a person with pre-existing HSV-1 antibody acquires HSV-2 genital infection (or vice versa), a first-episode nonprimary infection ensues. Viral reactivation from latency and subsequent antegrade translocation of virus back to skin and mucosal surfaces produces a recurrent infection.

Genital HSV infection can be either clinically apparent (eg, genital lesions) or inapparent (asymptomatic, or sub-clinical). Transmission to the neonate at the time of birth can occur with either presentation.

The distinction between neonatal HSV infection and neonatal HSV disease warrants discussion. Infection occurs when viral replication has been established, but the virus is not causing illness. Disease occurs when viral replication produces clinical signs of illness (eg, skin lesions, encephalitis, hepatitis). Once an infant is infected with HSV, progression to neonatal HSV disease is virtually certain. In an effort to prevent this progression from neonatal infection to neonatal disease, experts have recommended for many years that parenteral acyclovir be administered preemptively to HSV-infected neonates.<sup>6</sup>

### RISK OF MATERNAL INFECTION DURING PREGNANCY

Recurrent infections are the most common form of genital HSV during pregnancy.<sup>7</sup> Approximately 10% of HSV-2-seronegative pregnant women have an HSV-2-seropositive sexual partner and, thus, are at risk for contracting a primary HSV-2 infection during the pregnancy<sup>8</sup> and transmitting the virus to their infants during delivery. Approximately one-fifth to one-third of women of childbearing age are seronegative for both HSV-1 and HSV-2,<sup>9,10</sup> and, among discordant couples, the chance that a woman will acquire either virus during pregnancy is estimated to be 3.7%.<sup>11</sup> For women who are already seropositive for HSV-1, the estimated chance of HSV-2 acquisition during the pregnancy is 1.7%.<sup>11</sup> Approximately two-thirds of women who acquire genital herpes during pregnancy remain asymptomatic and have no symptoms to suggest a genital HSV infection.<sup>11</sup> This is consistent with the finding that 60% to 80% of women who deliver an HSV-infected infant have a clinically unapparent genital HSV infection at the time of delivery and have neither a past history of genital herpes nor a sexual partner reporting a history of genital HSV.<sup>12–14</sup>

### RISK OF NEONATAL HSV INFECTION

HSV infection of the newborn infant is acquired during 1 of 3 distinct times: intrauterine (in utero), intrapartum (perinatal), and postpartum (postnatal). The time of transmission of HSV-1 or HSV-2 for the overwhelming majority of infected infants (~85%) is in the intrapartum period. An additional 10% of infected neonates acquire HSV-1 postnatally from either a maternal or non-maternal source, and the final 5% are infected with HSV-2 or HSV-1 in utero. Five factors known to influence transmission of HSV from mother to neonate are:

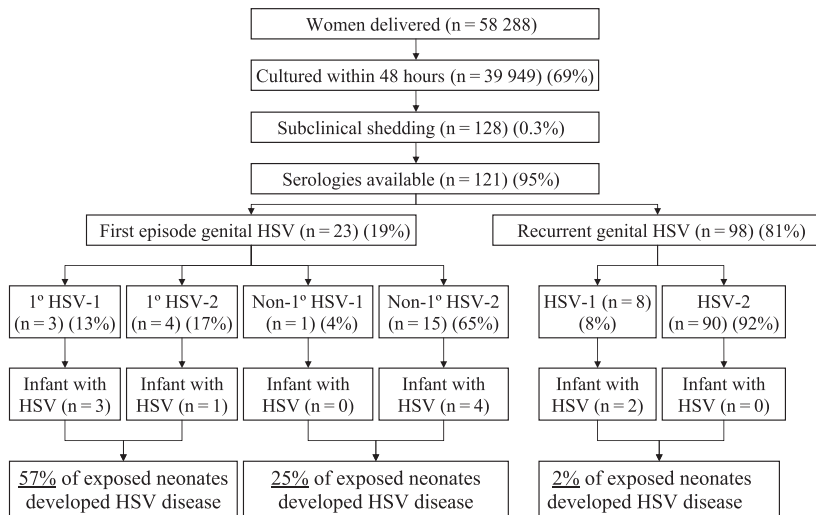
1. Type of maternal infection (primary versus recurrent)<sup>5,15–18</sup>;
2. Maternal HSV antibody status<sup>5,14,19,20</sup>;
3. Duration of rupture of membranes<sup>18</sup>;
4. Integrity of mucocutaneous barriers (eg, use of fetal scalp electrodes)<sup>5,21,22</sup>; and
5. Mode of delivery (cesarean versus vaginal delivery).<sup>5</sup>

Infants born to mothers who have a first episode of genital HSV infection near term and are shedding virus at delivery are at much greater risk of developing neonatal herpes than are infants whose mothers have recurrent genital herpes (Fig 1).<sup>5,15–18</sup>

The largest assessment of the influence of type of maternal infection on likelihood of neonatal transmission is a landmark study involving almost 60 000 women in labor who did not have clinical evidence of genital HSV disease, approximately 40 000 of whom had cultures performed within 48 hours of delivery (Fig 1).<sup>5</sup> Of these, 121 women were identified who were asymptotically shedding HSV and who had sera available for analysis. In this large trial, 57% of infants delivered to women with first-episode primary HSV infection developed neonatal HSV disease, compared with 25% of infants delivered to women with first-episode nonprimary infection and 2% of infants delivered to women with recurrent HSV disease (Fig 1).<sup>5</sup>

### CLINICAL MANIFESTATIONS OF NEONATAL HSV DISEASE

HSV infections acquired either intrapartum or postpartum can be classified as: (1) disease involving multiple visceral organs, including lung, liver, adrenal glands, skin, eye, and/or brain (disseminated disease); (2) central nervous system (CNS) disease, with or without skin lesions (CNS disease); and (3) disease limited to the skin, eyes, and/or mouth (skin, eye, mouth [SEM]

**FIGURE 1**

Type of maternal infection and risk of HSV transmission to the neonate.<sup>5</sup>

disease). This classification system is predictive of both morbidity and mortality.<sup>23–27</sup> Neonates with disseminated and SEM HSV disease typically present for medical attention at 10 to 12 days of age, whereas infants with CNS disease typically present at 17 to 19 days of age.<sup>24</sup> Overall, approximately half of all infants with neonatal HSV disease will have CNS involvement (CNS disease or disseminated disease with CNS involvement), and approximately 70% will have characteristic vesicular skin lesions (SEM disease, 83%; CNS disease, 63%; disseminated disease, 58%).<sup>24</sup>

### DIAGNOSIS OF GENITAL HSV DISEASE

HSV can be detected from genital lesions by polymerase chain reaction (PCR) assay, viral culture, or antigen detection. Of these, PCR assay or viral culture are the testing modalities recommended by the Centers for Disease Control and Prevention for the diagnosis of genital HSV lesions.<sup>28</sup> The sensitivity of viral culture from genital lesions is low, especially for recurrent infection, and declines rapidly as lesions begin to heal. PCR assays for HSV DNA are more sensitive and are increasingly used for the diagnosis of genital HSV.<sup>28,29</sup> A

potential limitation of the PCR assay at the current time relates to its availability in all clinical settings; some smaller or more remote medical facilities have limited or no access to laboratories offering this technology. At many tertiary care centers, PCR assay results may be available within a day, whereas it takes 2 to 5 days for HSV to grow in viral culture. Typing of an HSV culture isolate or PCR assay product to determine if it is HSV-1 or HSV-2 can be accomplished by one of several techniques. The reliability of viral culture depends on the stage of the episode, with higher quantities of virus being present during the prodromal and vesicular stages than during crusting.<sup>30</sup> Antigen detection methods are available commercially but may not distinguish HSV-1 from HSV-2 and are not recommended by the Centers for Disease Control and Prevention for the diagnosis of genital herpes.

Before the year 2000, commercially available serological assays were unable to distinguish between HSV-1 and HSV-2 antibodies, severely limiting their utility. Over the past decade, a number of type-specific serological assays that reliably distinguish between immunoglobulin G (IgG) directed against HSV-1 and HSV-2

have been approved by the US Food and Drug Administration (Table 1). Many of these products are sold in kits that are used by clinical laboratories throughout the United States. Several additional tests that claim to distinguish between HSV-1 and HSV-2 antibody are available commercially, but high cross-reactivity rates attributable to their use of crude antigen preparations limit their utility,<sup>31</sup> and their use is not recommended.

### DIAGNOSIS OF NEONATAL HSV DISEASE

Isolation of HSV by culture remains the definitive diagnostic method of establishing neonatal HSV disease. If skin lesions are present, a scraping of the vesicles should be transferred in appropriate viral transport media on ice to a diagnostic virology laboratory.<sup>6</sup> Other sites from which specimens should be obtained for culture of HSV include the conjunctivae, mouth, nasopharynx, and rectum (“surface cultures”).<sup>6</sup> Specimens for viral culture from mucosal body sites may be combined before inoculating in cell culture to decrease costs, because the important information gathered from such cultures is the presence or absence of replicating virus rather than its precise body site. The sensitivity of PCR assay on surface specimens has not been studied; if used, surface PCR assay should be performed in addition to (and not instead of) the gold-standard surface culture. Rapid diagnostic techniques also are available, such as direct fluorescent antibody staining of vesicle scrapings or enzyme immunoassay detection of HSV antigens. These techniques are as specific but slightly less sensitive than culture.

The diagnosis of neonatal HSV CNS disease has been greatly enhanced by PCR testing of cerebrospinal fluid (CSF) specimens,<sup>32–38</sup> and PCR assay is now the method of choice for documenting CNS involvement in an infant

**TABLE 1** Quick Reference Guide for Blood Tests to Accurately Detect Type-Specific HSV Antibodies

	Biokit USA	Bio-Rad Laboratories	Trinity Biotech USA	Euroimmun US LLC	Focus Diagnostics	HerpeSelect HSV-1 ELISA and HerpeSelect HSV-2 ELISA	HerpeSelect 1 and 2 Differentiation Immunoblot	Liaison HSV-2	AtheNA Multilyte
Supplier	Biokit USA	Bio-Rad Laboratories	Trinity Biotech USA	Euroimmun US LLC	Focus Diagnostics	HerpeSelect HSV-1 ELISA and HerpeSelect HSV-2 ELISA	HerpeSelect 1 and 2 Differentiation Immunoblot	Liaison HSV-2	AtheNA Multilyte
FDA approved Antibodies detected	1999 HSV-2 only	2009 HSV-1 or HSV-2 or both	2004 HSV-1 or HSV-2 or both	2007 HSV-1 or HSV-2	2000/2002 HSV-1 or HSV-2 or both	2000 HSV-1 and/or HSV-2	2008 HSV-1 or HSV-2	2008 HSV-1 and/or HSV-2	2008 HSV-1 and/or HSV-2
Best use of test	POC test to screen or test individuals >3 mo postexposure	Screening or testing (high volume)	Screening or testing pregnant women or STD clinic patients (moderate volume)	Moderate volume	Screening or testing STD patients or pregnant women (moderate volume)	Low volume	High volume	Screening or testing (moderate to high volume)	
Collection method	Finger stick, whole blood, or serum in clinic	Blood draw (sent to laboratory)	Blood draw (sent to laboratory)	Blood draw (sent to laboratory)	Blood draw (sent to laboratory)	Blood draw (sent to laboratory)	Blood draw (sent to laboratory)	Blood draw (sent to laboratory)	
Test time	10 min	45 min	~2 h	~2 h	~2 h	~2 h	35 min	~2 h	
FDA approved for use during pregnancy	Limited	Yes	Yes	Yes	Yes	Yes			
Test availability	Limited	Widely available	Widely available	Widely available	Widely available	Widely available			
Web site	www.biokitusa.com	www.bio-rad.com	www.trinitybiotech.com	www.euroimmunus.com	www.herpeselect.com	www.herpeselect.com	www.diasorin.com	www.invernessmedical.com	
For more information	800-926-3553	800-224-6723	800-325-3424	800-913-2022			800-328-5669	877-546-8633	

FDA, US Food and Drug Administration; POC, point of care; STD, sexually transmitted disease. Adapted from <http://www.washastd.org/>. Accessed August 5, 2010.

suspected of having HSV disease. However, PCR assay of CSF should only be performed in conjunction with HSV surface cultures, given that up to 40% of infants with disseminated disease will not have CNS involvement, and, by definition, no infants with SEM disease will have CNS involvement. The sensitivity of CSF PCR testing in neonatal HSV disease ranges from 75% to 100%.<sup>33,36,38</sup> PCR analysis of CSF also should play a role in determining the duration of antiviral therapy, because available data suggest that having HSV DNA detected in CSF at or after completion of intravenous therapy is associated with poor outcomes.<sup>36,37</sup> All infants with a positive CSF PCR assay result for HSV DNA at the beginning of antiviral therapy should have a repeat lumbar puncture near the end of treatment to determine that HSV DNA has been cleared from the CNS.<sup>24</sup> Infants whose PCR assay result remains positive should continue to receive intravenous antiviral therapy until the CSF PCR assay result is negative.<sup>24,36</sup>

Application of PCR testing to blood specimens from infants with suspected HSV disease appears promising,<sup>37-42</sup> and, in the 2012 *Red Book*,<sup>6</sup> PCR assay of blood has been added to the laboratory evaluation for neonatal HSV disease. Data are insufficient at the current time to allow the use of serial PCR assays of blood to establish response to antiviral therapy or to guide decisions about the duration of therapy.

Serological testing is not helpful in the diagnosis of neonatal HSV infection, because transplacentally acquired maternal HSV IgG is present in most infants, given the substantial proportions of the adult American population who are HSV-1 and/or HSV-2 seropositive.

## PREVENTION OF NEONATAL HSV DISEASE

Cesarean delivery in a woman with active genital lesions can reduce the infant's risk of acquiring HSV.<sup>5,18</sup> In



1999, the American College of Obstetricians and Gynecologists updated its management guidelines for genital herpes in pregnancy.<sup>43</sup> To reduce the risk of neonatal HSV disease, cesarean delivery should be performed if genital HSV lesions or prodromal symptoms are present at the time of delivery. Neonatal HSV infection has occurred despite cesarean delivery performed before the rupture of membranes.<sup>12,44</sup>

In women with a previous diagnosis of genital herpes, cesarean delivery to prevent neonatal HSV infection is not indicated if there are no genital lesions at the time of labor. In an effort to reduce cesarean deliveries performed for the indication of genital herpes, the use of oral acyclovir or valacyclovir near the end of pregnancy to suppress genital HSV recurrences has become increasingly common in obstetric practice. Several studies with small sample sizes suggest that suppressive acyclovir therapy during the last weeks of pregnancy decreases the occurrence of clinically apparent genital HSV disease at the time of delivery,<sup>45–48</sup> with an associated decrease in cesarean delivery rates for the indication of genital HSV.<sup>45,46,49,50</sup> However, because viral shedding still occurs (albeit with reduced frequency),<sup>47,51</sup> the potential for neonatal infection is not avoided completely, and cases of neonatal HSV disease in newborn infants of women who were receiving antiviral suppression recently have been reported.<sup>52,53</sup>

### **ALGORITHM FOR MANAGEMENT OF ASYMPTOMATIC NEONATES BORN VAGINALLY OR BY CESAREAN DELIVERY TO WOMEN WITH ACTIVE GENITAL HSV LESIONS (FIGS 2 AND 3)**

The risk of transmitting HSV to the newborn infant during delivery is influenced directly by the mother's previous immunity to HSV; women who have primary genital HSV infections who are

shedding HSV at delivery are 10 to 30 times more likely to transmit the virus to their newborn infants than women with a recurrent infection.<sup>5</sup> The increased risk is attributable both to lower concentrations of transplacental HSV-specific antibodies (which also are less reactive to expressed polypeptides) in women with primary infection<sup>19</sup> and to the higher quantities of HSV that are shed for a longer period of time in the maternal genital tract in comparison with women who have recurrent genital HSV infection.<sup>54</sup> However, a substantial percentage of women with first clinical episodes of symptomatic genital herpes actually are experiencing reactivation of a previously unrecognized genital herpetic infection.<sup>55</sup> Thus, to tailor management of exposed neonates according to their degree of risk, one must distinguish primary versus recurrent maternal HSV infection in a manner that relies on more than just the history, or lack thereof, of genital herpes in the woman or her partner (s). Ideally, detection of HSV DNA from genital swabs obtained from women in labor would identify both symptomatic and asymptomatic HSV shedding, allowing for focused management of only those infants who are exposed; however, the technology to accomplish this on a broad scale is not readily available commercially at this time.

With the approval of commercially available serological tests that can reliably distinguish type-specific HSV antibodies (Table 1), the means to further refine management of asymptomatic neonates delivered to women with active genital HSV lesions is now possible. The algorithm detailed in Figs 2 and 3 applies only to asymptomatic neonates after vaginal or cesarean (because cesarean delivery reduces but does not eliminate the risk of neonatal HSV disease) delivery to women with active genital HSV lesions. It is intended to outline 1 approach to the management

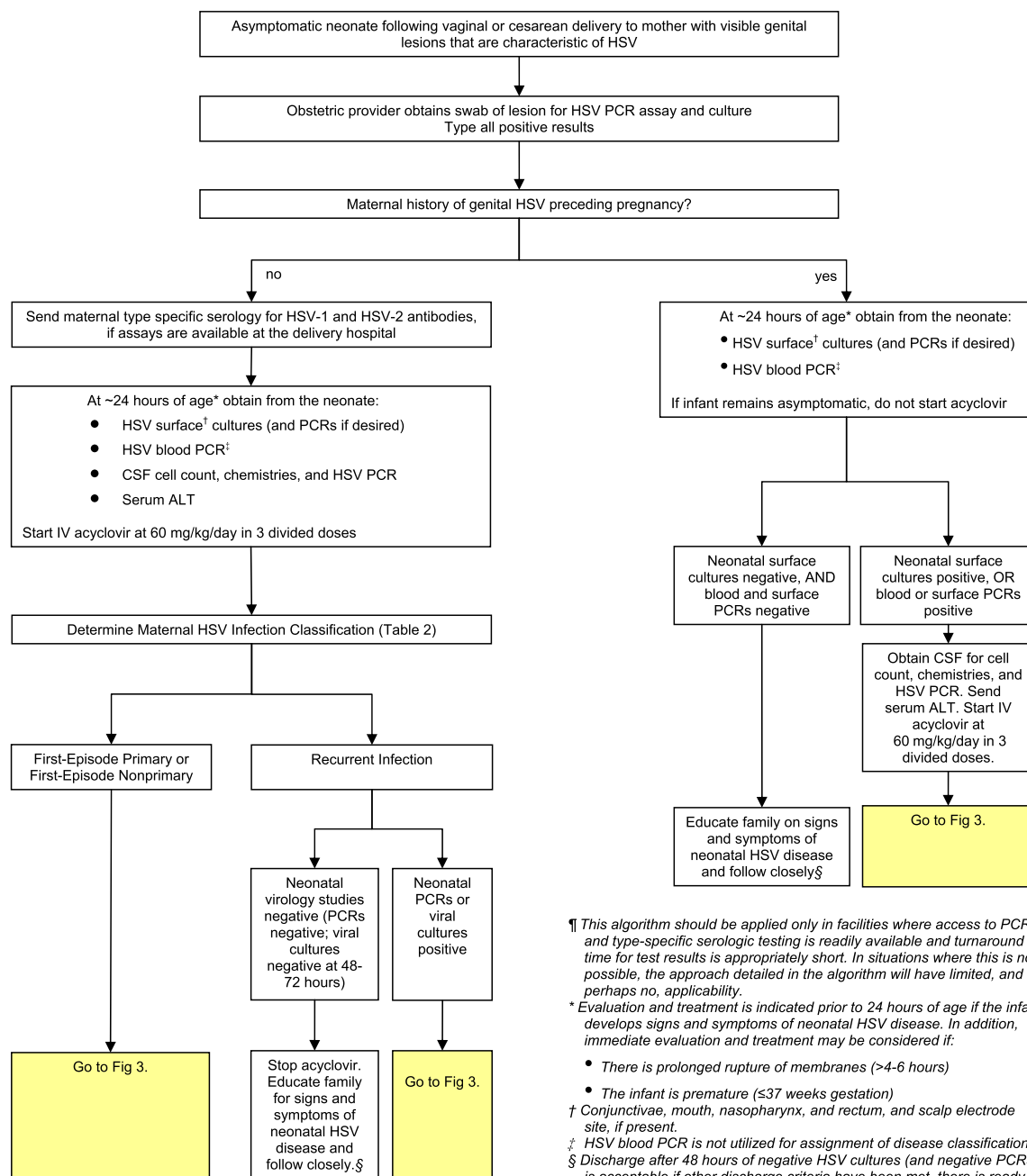
of these infants and may not be feasible in settings with limited access to PCR assays for HSV DNA or to the newer type-specific serological tests. If, at any point during the evaluation outlined in the algorithm, an infant develops symptoms that could possibly indicate neonatal HSV disease (fever, hypothermia, lethargy, irritability, vesicular rash, seizures, etc), a full diagnostic evaluation should be undertaken, and intravenous acyclovir therapy should be initiated. In applying this algorithm, obstetric providers and pediatricians likely will need to work closely with their diagnostic laboratories to ensure that serological and virological testing is available and turnaround times are acceptable. In situations in which this is not possible, the approach detailed in the algorithm will have limited, and perhaps no, applicability.

### **TESTING OF WOMEN IN LABOR**

Women in labor with visible genital lesions that are characteristic of HSV should have the lesions swabbed for HSV PCR and culture (AI). Any positive test result then requires further analysis to determine if the virus is HSV-1 or HSV-2. Correlation of viral type with serological status allows for determination of maternal infection classification (Table 2).

### **Management of Asymptomatic Neonates After Vaginal or Cesarean Delivery to Women With Lesions at Delivery and History of Genital HSV Preceding Pregnancy**

For women with a history of genital herpes preceding the pregnancy, the likelihood that the current outbreak represents reactivation of latent HSV is high, and, therefore, the likelihood of transmission to the infant is low (2%). Skin and mucosal specimens (conjunctivae, mouth, nasopharynx, and rectum, and scalp electrode site, if present) should be obtained from the



¶ This algorithm should be applied only in facilities where access to PCR and type-specific serologic testing is readily available and turnaround time for test results is appropriately short. In situations where this is not possible, the approach detailed in the algorithm will have limited, and perhaps no, applicability.

\* Evaluation and treatment is indicated prior to 24 hours of age if the infant develops signs and symptoms of neonatal HSV disease. In addition, immediate evaluation and treatment may be considered if:

- There is prolonged rupture of membranes (>4-6 hours)
- The infant is premature ( $\leq 37$  weeks gestation)

† Conjunctivae, mouth, nasopharynx, and rectum, and scalp electrode site, if present.

‡ HSV blood PCR is not utilized for assignment of disease classification.

§ Discharge after 48 hours of negative HSV cultures (and negative PCRs) is acceptable if other discharge criteria have been met, there is ready access to medical care, and a person who is able to comply fully with instructions for home observation will be present. If any of these conditions is not met, the infant should be observed in the hospital until HSV cultures are finalized as negative or are negative for 96 hours after being set up in cell culture, whichever is shorter.

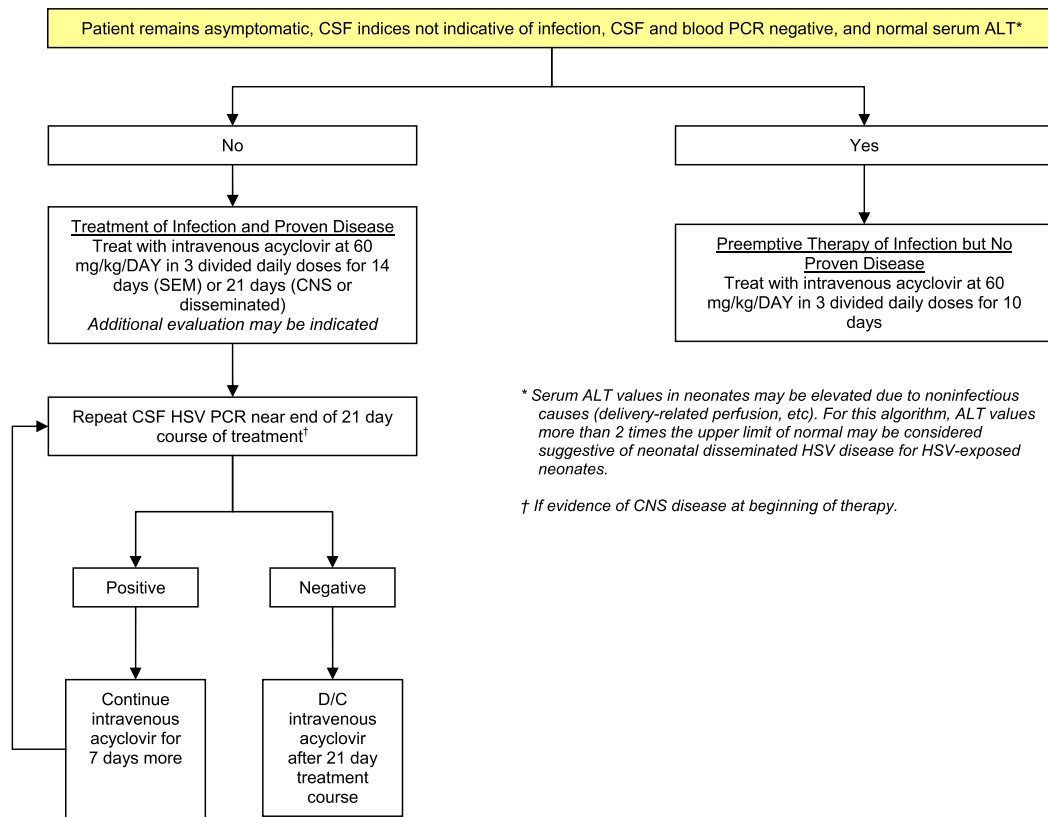
**FIGURE 2**

Algorithm for the evaluation of asymptomatic neonates after vaginal or cesarean delivery to women with active genital herpes lesions. ALT, alanine aminotransferase; D/C, discontinue.

neonate for culture (and PCR assay, if desired) at approximately 24 hours after delivery (BII), and blood should be sent for HSV DNA PCR assay. Acyclovir need not be started as long as the infant remains asymptomatic (BIII).

The importance of waiting until approximately 24 hours after delivery to obtain virological studies is based on the fact that a positive virological test result at that point represents actively replicating virus on the infant's mucosa,

whereas a positive test result shortly after birth could reflect only transient maternal contamination that may not lead to replication with resulting neonatal HSV disease.<sup>56</sup> It is permissible to discharge an asymptomatic infant after



**FIGURE 3**

Algorithm for the treatment of asymptomatic neonates after vaginal or cesarean delivery to women with active genital herpes lesions. ALT, alanine aminotransferase; D/C, discontinue.

48 hours of negative HSV cultures (and negative PCR assay results) if other discharge criteria have been met, there is ready access to medical care, and a person who is able to comply fully with instructions for home observation will be present (BIII). If any of these conditions is not met, the infant should be observed in the hospital until HSV cultures are finalized as negative or are negative for 96 hours after being set up in cell culture, whichever is shorter.

If the surface and blood virological study results are negative at 5 days, the infant should be evaluated if signs or symptoms of neonatal HSV disease develop during the first 6 weeks of life (AII). Conversely, if the surface and blood virological study results become positive, thus confirming neonatal HSV infection, the infant should undergo a complete evaluation (lumbar puncture with CSF sent for indices and HSV DNA PCR assay, in addition to serum alanine

transaminase) to determine the extent of disease, and intravenous acyclovir should be initiated as soon as possible. If the evaluation findings are normal, indicating that the neonate has HSV infection but that it has not yet progressed to HSV disease, the infant should be treated empirically with intravenous acyclovir for 10 days to prevent progression from infection to disease (preemptive therapy) (BIII). If the evaluation findings are abnormal,

**TABLE 2** Maternal Infection Classification by Genital HSV Viral Type and Maternal Serology<sup>a</sup>

Classification of Maternal Infection	PCR/Culture From Genital Lesion	Maternal HSV-1 and HSV-2 IgG Antibody Status
Documented first-episode primary infection	Positive, either virus	Both negative
Documented first-episode nonprimary infection	Positive for HSV-1 Positive for HSV-2	Positive for HSV-2 AND negative for HSV-1 Positive for HSV-1 AND negative for HSV-2
Assume first-episode (primary or nonprimary) infection	Positive for HSV-1 OR HSV-2 Negative OR not available <sup>b</sup>	Not available Negative for HSV-1 and/or HSV-2 OR not available
Recurrent infection	Positive for HSV-1 Positive for HSV-2	Positive for HSV-1 Positive for HSV-2

<sup>a</sup> To be used for women without a clinical history of genital herpes.

<sup>b</sup> When a genital lesion is strongly suspicious for HSV, clinical judgment should supersede the virological test results for the conservative purposes of this neonatal management algorithm. Conversely, if in retrospect, the genital lesion was not likely to be caused by HSV and the PCR assay result or culture is negative, departure from the evaluation and management in this conservative algorithm may be warranted.

indicating the neonate already has neonatal HSV disease, the infant should be treated for 14 to 21 days with intravenous acyclovir on the basis of the extent of neonatal HSV disease (disseminated, CNS, or SEM) (All); if the initial CSF PCR assay result is positive for HSV DNA, a repeat lumbar puncture should be obtained near the end of therapy (eg, on day 17 or 18 of an anticipated 21-day course of therapy), and intravenous acyclovir should be discontinued at 21 days if the repeat HSV PCR assay result is negative (All). If the "end-of-therapy" CSF PCR assay result is positive, intravenous acyclovir should be continued for another 7 days, with another repeat lumbar puncture near the end of therapy, again with decisions regarding cessation of therapy predicated on the repeat HSV CSF PCR assay result (BII). After completion of parenteral acyclovir for treatment of neonatal HSV disease, infants should receive oral acyclovir suppressive therapy for 6 months.<sup>57</sup>

### **Management of Asymptomatic Neonates After Vaginal or Cesarean Delivery to Women With Lesions at Delivery and No History of Genital HSV Preceding Pregnancy**

For women without a history of genital herpes preceding pregnancy, the presence of genital lesions at delivery could represent first-episode primary infection (with a risk of transmission to the newborn infant of 57%), first-episode nonprimary infection (with a risk of transmission to the newborn infant of 25%), or recurrent infection (with a risk of transmission to the newborn infant of 2%). Thus, with the availability of type-specific serological testing, the practitioner can determine which type of infection the outbreak represents, given that the risks to the infant are so disparate. Accordingly, serological testing should be performed to determine the type of HSV infection in the mother to delineate between the 3 (Table 1).

At approximately 24 hours after delivery, neonatal skin and mucosal specimens (conjunctivae, mouth, nasopharynx, and rectum, and scalp electrode site, if present) should be obtained for culture (and PCR assay, if desired), and blood should be sent for HSV DNA PCR assay to evaluate for HSV infection. In addition, the infant should be evaluated for neonatal HSV disease (lumbar puncture with CSF sent for indices and HSV DNA PCR assay, in addition to serum alanine transaminase) at the same time, and intravenous acyclovir should be initiated pending the results of the evaluation, because the possibility is high that this could be a primary maternal infection (BIII). It is acceptable to wait to initiate therapy until approximately 24 hours after delivery in an asymptomatic neonate, because the average age at onset of neonatal HSV disease is between 1.5 and 3 weeks of age. Some practitioners advocate evaluation and treatment immediately after delivery if the infant is preterm or there has been prolonged rupture of membranes (CIII).

Laboratory correlations between virological (PCR/culture) and serological results that define maternal disease classification (first-episode primary, first-episode nonprimary, and recurrent) are presented in Table 2. The table deliberately uses a conservative estimate of first-episode infection, because the likelihood of transmission in such a situation is high. It is intended to be used to determine maternal disease classification in women without a clinical history of genital herpes.

If the mother has a documented or assumed first-episode primary or first-episode nonprimary infection (Table 2) and the neonate's evaluation results are normal, the infant should be treated empirically with intravenous acyclovir for 10 days to prevent progression from neonatal infection to disease (preemptive therapy) (BIII). If

the infant's evaluation results are abnormal, indicating the neonate already has neonatal HSV disease, the infant should be treated for 14 to 21 days with intravenous acyclovir on the basis of the extent of neonatal HSV disease (disseminated, CNS, or SEM) (All); if the initial CSF PCR assay results are positive for HSV DNA, a repeat lumbar puncture should be obtained near the anticipated end of therapy (eg, on day 17 or 18 of therapy), and intravenous acyclovir should be discontinued at 21 days if the repeat HSV PCR assay result is negative (All). If the end-of-therapy CSF PCR assay result is positive, the intravenous acyclovir should be continued for another 7 days, with another repeat lumbar puncture near the anticipated new end of therapy, again with decisions regarding cessation of therapy predicated on the HSV CSF PCR assay result (BII). After completion of parenteral acyclovir for treatment of neonatal HSV disease, infants should receive oral acyclovir suppressive therapy for 6 months.<sup>57</sup>

If the mother has recurrent genital HSV infection (that is, she has type-specific antibody to the HSV serotype detected by her genital swab) and the neonatal surface and blood virology study results are negative, acyclovir should be stopped, the parent(s) should receive education regarding signs and symptoms of neonatal HSV, and the infant may be discharged and reevaluated with any signs or symptoms of illness during the first 6 weeks of life (All). Conversely, if virology study results are positive, confirming neonatal HSV infection, intravenous acyclovir should be continued, with the duration of treatment based on the evaluation for neonatal HSV disease. If the evaluation findings are normal, the infant should be treated empirically with intravenous acyclovir for 10 days to prevent progression from HSV



infection to HSV disease (preemptive therapy) (BIII). If the evaluation findings are abnormal, the infant should be treated with intravenous acyclovir for 14 to 21 days on the basis of the extent of neonatal HSV disease (disseminated, CNS, or SEM) (AII); if the initial CSF PCR assay result is positive for HSV DNA, a repeat lumbar puncture should be obtained near the end of therapy (eg, on day 17 or 18 of an anticipated 21-day course of therapy), and intravenous acyclovir should be discontinued at 21 days if the repeat HSV PCR assay result is negative (AII). If the end-of-therapy CSF PCR assay result is positive, intravenous acyclovir should be continued for another 7 days, with another repeat lumbar puncture near the end of therapy, again with decisions regarding cessation of therapy predicated on the basis of HSV CSF PCR assay result (BII). After completion of parenteral acyclovir for treatment of neonatal HSV disease, infants should receive oral acyclovir suppressive therapy for 6 months.<sup>57</sup>

#### COMMITTEE ON INFECTIOUS DISEASES, 2012–2013

Michael T. Brady, MD, Chairperson  
Carrie L. Byington, MD  
H. Dele Davies, MD

#### REFERENCES

- Fleming DT, McQuillan GM, Johnson RE, et al. Herpes simplex virus type 2 in the United States, 1976 to 1994. *N Engl J Med*. 1997;337(16):1105–1111
- Xu F, McQuillan GM, Kottiri BJ, et al. Trends in herpes simplex virus type 2 infection in the United States. In: 42nd Annual Meeting of the Infectious Diseases Society of America; September 30–October 3, 2004; Boston, MA. Abstract 739
- Lafferty WE, Downey L, Celum C, Wald A. Herpes simplex virus type 1 as a cause of genital herpes: impact on surveillance and prevention. *J Infect Dis*. 2000;181(4):1454–1457
- Kimberlin DW, Rouse DJ. Clinical practice. Genital herpes. *N Engl J Med*. 2004;350(19):1970–1977
- Brown ZA, Wald A, Morrow RA, Selke S, Zeh J, Corey L. Effect of serologic status and cesarean delivery on transmission rates of herpes simplex virus from mother to infant. *JAMA*. 2003;289(2):203–209
- American Academy of Pediatrics. Herpes simplex. In: Pickering LK, Baker CJ, Kimberlin DW, Long SS, eds. *Red Book: 2012 Report of the Committee on Infectious Diseases*. 29th ed. Elk Grove Village, IL: American Academy of Pediatrics; 2012:398–408
- Whitley RJ. Herpes simplex virus infections. In: Remington JS, Klein JO, eds. *Infectious Diseases of the Fetus and Newborn Infants*. 3rd ed. Philadelphia, PA: WB Saunders Co; 1990:282–305
- Kulhanjian JA, Soroush V, Au DS, et al. Identification of women at unsuspected risk of primary infection with herpes simplex virus type 2 during pregnancy. *N Engl J Med*. 1992;326(14):916–920
- Xu F, Schillinger JA, Sternberg MR, et al. Seroprevalence and coinfection with herpes simplex virus type 1 and type 2 in the United States, 1988–1994. *J Infect Dis*. 2002;185(8):1019–1024
- Xu F, Sternberg MR, Kottiri BJ, et al. Trends in herpes simplex virus type 1 and type 2 seroprevalence in the United States. *JAMA*. 2006;296(8):964–973
- Brown ZA, Selke S, Zeh J, et al. The acquisition of herpes simplex virus during pregnancy. *N Engl J Med*. 1997;337(8):509–515
- Whitley RJ, Corey L, Arvin A, et al. Changing presentation of herpes simplex virus

Kathryn M. Edwards, MD  
Mary P. Glode, MD  
Mary Anne Jackson, MD  
Harry L. Keyserling, MD  
Yvonne A. Maldonado, MD  
Dennis L. Murray, MD  
Walter A. Orenstein, MD  
Gordon E. Schutze, MD  
Rodney E. Willoughby, MD  
Theoklis E. Zaoutis, MD

#### LIAISONS

Marc A. Fischer, MD – *Centers for Disease Control and Prevention*  
Bruce Gellin, MD – *National Vaccine Program Office*  
Richard L. Gorman, MD – *National Institutes of Health*  
Lucia Lee, MD – *Food and Drug Administration*  
R. Douglas Pratt, MD – *Food and Drug Administration*  
Jennifer S. Read, MD – *National Vaccine Program Office*  
Joan Robinson, MD – *Canadian Pediatric Society*  
Marco Aurelio Palazzi Safadi, MD – *Sociedad Latinoamericana de Infectologia Pediatrica (SLIPE)*  
Jane Seward, MBBS, MPH – *Centers for Disease Control and Prevention*  
Jeffrey R. Starke, MD – *American Thoracic Society*  
Geoffrey Simon, MD – *Committee on Practice Ambulatory Medicine*  
Tina Q. Tan, MD – *Pediatric Infectious Diseases Society*

#### EX OFFICIO

Henry H. Bernstein, DO – *Red Book Online Associate Editor*

David W. Kimberlin, MD – *Red Book Editor*  
Sarah S. Long, MD – *Red Book Associate Editor*  
H. Cody Meissner, MD – *Visual Red Book Associate Editor*

#### STAFF

Jennifer Frantz, MPH

#### COMMITTEE ON FETUS AND NEWBORN, 2012–2013

Lu-Ann Papile, MD, Chairperson  
Jill E. Baley, MD  
William Benitz, MD  
Waldemar A. Carlo, MD  
James Cummings, MD  
Eric Eichenwald, MD  
Praveen Kumar, MD  
Richard A. Polin, MD  
Rosemarie C. Tan, MD, PhD  
Kasper S. Wang, MD

#### FORMER MEMBER

Kristi L. Watterberg, MD

#### LIAISONS

CAPT Wanda D. Barfield, MD, MPH – *Centers for Disease Control and Prevention*  
George Macones, MD – *American College of Obstetricians and Gynecologists*  
Ann L. Jefferies, MD – *Canadian Pediatric Society*  
Erin L. Keels, APRN, MS, NNP-BC – *National Association of Neonatal Nurses*  
Tonse N.K. Raju, MD, DCH – *National Institutes of Health*

#### STAFF

Jim Couto, MA

- infection in neonates. *J Infect Dis*. 1988;158(1):109–116
13. Whitley RJ, Nahmias AJ, Visintine AM, Fleming CL, Alford CA. The natural history of herpes simplex virus infection of mother and newborn. *Pediatrics*. 1980;66(4):489–494
  14. Yeager AS, Arvin AM. Reasons for the absence of a history of recurrent genital infections in mothers of neonates infected with herpes simplex virus. *Pediatrics*. 1984;73(2):188–193
  15. Brown ZA, Benedetti J, Ashley R, et al. Neonatal herpes simplex virus infection in relation to asymptomatic maternal infection at the time of labor. *N Engl J Med*. 1991;324(18):1247–1252
  16. Brown ZA, Vontver LA, Benedetti J, et al. Effects on infants of a first episode of genital herpes during pregnancy. *N Engl J Med*. 1987;317(20):1246–1251
  17. Corey L, Wald A. Genital herpes. In: Holmes KK, Sparling PF, Mardh PA, et al, eds. *Sexually Transmitted Diseases*. 3rd ed. New York, NY: McGraw-Hill; 1999:285–312
  18. Nahmias AJ, Josey WE, Naib ZM, Freeman MG, Fernandez RJ, Wheeler JH. Perinatal risk associated with maternal genital herpes simplex virus infection. *Am J Obstet Gynecol*. 1971;110(6):825–837
  19. Prober CG, Sullender WM, Yasukawa LL, Au DS, Yeager AS, Arvin AM. Low risk of herpes simplex virus infections in neonates exposed to the virus at the time of vaginal delivery to mothers with recurrent genital herpes simplex virus infections. *N Engl J Med*. 1987;316(5):240–244
  20. Yeager AS, Arvin AM, Urbani LJ, Kemp JA III. Relationship of antibody to outcome in neonatal herpes simplex virus infections. *Infect Immun*. 1980;29(2):532–538
  21. Parvey LS, Ch'ien LT. Neonatal herpes simplex virus infection introduced by fetal-monitor scalp electrodes. *Pediatrics*. 1980;65(6):1150–1153
  22. Kaye EM, Dooling EC. Neonatal herpes simplex meningoencephalitis associated with fetal monitor scalp electrodes. *Neurology*. 1981;31(8):1045–1047
  23. Kimberlin DW, Lin CY, Jacobs RF, et al; National Institute of Allergy and Infectious Diseases Collaborative Antiviral Study Group. Safety and efficacy of high-dose intravenous acyclovir in the management of neonatal herpes simplex virus infections. *Pediatrics*. 2001;108(2):230–238
  24. Kimberlin DW, Lin CY, Jacobs RF, et al; National Institute of Allergy and Infectious Diseases Collaborative Antiviral Study Group. Natural history of neonatal herpes simplex virus infections in the acyclovir era. *Pediatrics*. 2001;108(2):223–229
  25. Whitley R, Arvin A, Prober C, et al; Infectious Diseases Collaborative Antiviral Study Group. A controlled trial comparing vidarabine with acyclovir in neonatal herpes simplex virus infection. *N Engl J Med*. 1991;324(7):444–449
  26. Whitley R, Arvin A, Prober C, et al; The National Institute of Allergy and Infectious Diseases Collaborative Antiviral Study Group. Predictors of morbidity and mortality in neonates with herpes simplex virus infections. *N Engl J Med*. 1991;324(7):450–454
  27. Whitley RJ, Nahmias AJ, Soong SJ, Galasso GG, Fleming CL, Alford CA. Vidarabine therapy of neonatal herpes simplex virus infection. *Pediatrics*. 1980;66(4):495–501
  28. Workowski KA, Berman S; Centers for Disease Control and Prevention (CDC). Sexually transmitted diseases treatment guidelines, 2010 [published correction appears in *MMWR Recomm Rep*. 2011;60(1):18]. *MMWR Recomm Rep*. 2010;59(RR-12):1–110
  29. Wald A, Huang ML, Carrell D, Selke S, Corey L. Polymerase chain reaction for detection of herpes simplex virus (HSV) DNA on mucosal surfaces: comparison with HSV isolation in cell culture. *J Infect Dis*. 2003;188(9):1345–1351
  30. Moseley RC, Corey L, Benjamin D, Winter C, Remington ML. Comparison of viral isolation, direct immunofluorescence, and indirect immunoperoxidase techniques for detection of genital herpes simplex virus infection. *J Clin Microbiol*. 1981;13(5):913–918
  31. Ashley RL. Sorting out the new HSV type specific antibody tests. *Sex Transm Infect*. 2001;77(4):232–237
  32. Rowley AH, Whitley RJ, Lakeman FD, Wolinsky SM. Rapid detection of herpes-simplex-virus DNA in cerebrospinal fluid of patients with herpes simplex encephalitis. *Lancet*. 1990;335(8687):440–441
  33. Troendle-Atkins J, Demmler GJ, Buffone GJ. Rapid diagnosis of herpes simplex virus encephalitis by using the polymerase chain reaction. *J Pediatr*. 1993;123(3):376–380
  34. Anderson NE, Powell KF, Croxson MC. A polymerase chain reaction assay of cerebrospinal fluid in patients with suspected herpes simplex encephalitis. *J Neurol Neurosurg Psychiatry*. 1993;56(5):520–525
  35. Schlesinger Y, Storch GA. Herpes simplex meningitis in infancy. *Pediatr Infect Dis J*. 1994;13(2):141–144
  36. Kimberlin DW, Lakeman FD, Arvin AM, et al; National Institute of Allergy and Infectious Diseases Collaborative Antiviral Study Group. Application of the polymerase chain reaction to the diagnosis and management of neonatal herpes simplex virus disease. *J Infect Dis*. 1996;174(6):1162–1167
  37. Malm G, Forsgren M. Neonatal herpes simplex virus infections: HSV DNA in cerebrospinal fluid and serum. *Arch Dis Child Fetal Neonatal Ed*. 1999;81(1):F24–F29
  38. Kimura H, Futamura M, Kito H, et al. Detection of viral DNA in neonatal herpes simplex virus infections: frequent and prolonged presence in serum and cerebrospinal fluid. *J Infect Dis*. 1991;164(2):289–293
  39. Barbi M, Binda S, Primache V, Tettamanti A, Negri C, Brambilla C. Use of Guthrie cards for the early diagnosis of neonatal herpes simplex virus disease. *Pediatr Infect Dis J*. 1998;17(3):251–252
  40. Diamond C, Mohan K, Hobson A, Frenkel L, Corey L. Viremia in neonatal herpes simplex virus infections. *Pediatr Infect Dis J*. 1999;18(6):487–489
  41. Lewensohn-Fuchs I, Osterwall P, Forsgren M, Malm G. Detection of herpes simplex virus DNA in dried blood spots making a retrospective diagnosis possible. *J Clin Virol*. 2003;26(1):39–48
  42. Kimura H, Ito Y, Futamura M, et al. Quantitation of viral load in neonatal herpes simplex virus infection and comparison between type 1 and type 2. *J Med Virol*. 2002;67(3):349–353
  43. American College of Obstetricians and Gynecologists. ACOG Practice Bulletin. Clinical management guidelines for obstetrician-gynecologists. No 82 June 2007. Management of herpes in pregnancy. *Obstet Gynecol*. 2007;109(6):1489–1498
  44. Peng J, Krause PJ, Kresch M. Neonatal herpes simplex virus infection after cesarean section with intact amniotic membranes. *J Perinatol*. 1996;16(5):397–399
  45. Braig S, Luton D, Sibony O, et al. Acyclovir prophylaxis in late pregnancy prevents recurrent genital herpes and viral shedding. *Eur J Obstet Gynecol Reprod Biol*. 2001;96(1):55–58
  46. Scott LL, Sanchez PJ, Jackson GL, Zeray F, Wendel GD Jr. Acyclovir suppression to prevent cesarean delivery after first-episode genital herpes. *Obstet Gynecol*. 1996;87(1):69–73
  47. Scott LL, Hollier LM, McIntire D, Sanchez PJ, Jackson GL, Wendel GD Jr. Acyclovir suppression to prevent recurrent genital herpes at delivery. *Infect Dis Obstet Gynecol*. 2002;10(2):71–77
  48. Sheffield JS, Hollier LM, Hill JB, Stuart GS, Wendel GD Jr. Acyclovir prophylaxis to prevent herpes simplex virus recurrence at delivery: a systematic review. *Obstet Gynecol*. 2003;102(6):1396–1403
  49. Andrews WW, Kimberlin DF, Whitley R, Cliver S, Ramsey PS, Deeter R. Valacyclovir therapy

- to reduce recurrent genital herpes in pregnant women. *Am J Obstet Gynecol.* 2006;194(3):774–781
50. Sheffield JS, Hill JB, Hollier LM, et al. Valacyclovir prophylaxis to prevent recurrent herpes at delivery: a randomized clinical trial. *Obstet Gynecol.* 2006;108(1):141–147
51. Watts DH, Brown ZA, Money D, et al. A double-blind, randomized, placebo-controlled trial of acyclovir in late pregnancy for the reduction of herpes simplex virus shedding and cesarean delivery. *Am J Obstet Gynecol.* 2003;188(3):836–843
52. Pinninti SG, Feja KN, Kimberlin DW, et al. Neonatal herpes disease despite maternal antenatal antiviral suppressive therapy: a multicenter case series of the first such infants reported. In: 48th Annual Meeting of the Infectious Diseases Society of America; October 22, 2010; Vancouver, British Columbia. Abstract 1841
53. Pinninti SG, Angara R, Feja KN, et al. Neonatal herpes disease following maternal antenatal antiviral suppressive therapy: a multicenter case series. *J Pediatr.* 2012;161(1):134–138.e1–e3
54. Whitley RJ. Herpes simplex viruses. In: Fields BN, Knipe DM, Howley PM, et al, eds. *Fields Virology*. 3rd ed. Philadelphia, PA: Lippincott Raven Publishers; 1996:2297–2342
55. Diamond C, Selke S, Ashley R, Benedetti J, Corey L. Clinical course of patients with serologic evidence of recurrent genital herpes presenting with signs and symptoms of first episode disease. *Sex Transm Dis.* 1999;26(4):221–225
56. Turner R, Shehab Z, Osborne K, Hendley JO. Shedding and survival of herpes simplex virus from ‘fever blisters’. *Pediatrics.* 1982;70(4):547–549
57. Kimberlin DW, Whitley RJ, Wan W, et al; National Institute of Allergy and Infectious Diseases Collaborative Antiviral Study Group. Oral acyclovir suppression and neurodevelopment after neonatal herpes. *N Engl J Med.* 2011;365(14):1284–1292

**APPENDIX** Evidence-based Rating System Used To Determine Strength Of Recommendations

Category	Definition	Recommendation
Strength of recommendation		
A	Strong evidence for efficacy and substantial clinical benefit	Strongly recommended
B	Strong or moderate evidence for efficacy, but only limited clinical benefit	Generally recommended
C	Insufficient evidence for efficacy, or efficacy does not outweigh possible adverse consequences	Optional
D	Moderate evidence against efficacy or for adverse outcome	Generally not recommended
E	Strong evidence against efficacy or for adverse outcome	Never recommended
Quality of evidence supporting recommendation		
I	Evidence from at least 1 well-executed randomized controlled trial or 1 rigorously designed laboratory-based experimental study that has been replicated by an independent investigator	
II	Evidence from at least 1 well-designed clinical trial without randomization; cohort or case-controlled analytic studies (preferably from >1 center); multiple time-series studies; dramatic results from uncontrolled studies; or some evidence from laboratory experiments	
III	Evidence from opinions of respected authorities based on clinical or laboratory experience, descriptive studies, or reports of expert committees	

Adapted from Centers for Disease Control. 2009 guidelines for the prevention and treatment of opportunistic infections among HIV-exposed and HIV-infected children. *MMWR Recomm Rep.* 2009;58(RR-11):5.

## Guidance on Management of Asymptomatic Neonates Born to Women With Active Genital Herpes Lesions

David W. Kimberlin, Jill Baley, COMMITTEE ON INFECTIOUS DISEASES and COMMITTEE ON FETUS AND NEWBORN

*Pediatrics* 2013;131:e635

DOI: 10.1542/peds.2012-3216 originally published online January 28, 2013;

<b>Updated Information &amp; Services</b>	including high resolution figures, can be found at: <a href="http://pediatrics.aappublications.org/content/131/2/e635">http://pediatrics.aappublications.org/content/131/2/e635</a>
<b>References</b>	This article cites 51 articles, 13 of which you can access for free at: <a href="http://pediatrics.aappublications.org/content/131/2/e635.full#ref-list-1">http://pediatrics.aappublications.org/content/131/2/e635.full#ref-list-1</a>
<b>Subspecialty Collections</b>	This article, along with others on similar topics, appears in the following collection(s): <b>Current Policy</b> <a href="http://classic.pediatrics.aappublications.org/cgi/collection/current_policy">http://classic.pediatrics.aappublications.org/cgi/collection/current_policy</a> <b>Committee on Fetus &amp; Newborn</b> <a href="http://classic.pediatrics.aappublications.org/cgi/collection/committee_on_fetus_newborn">http://classic.pediatrics.aappublications.org/cgi/collection/committee_on_fetus_newborn</a> <b>Fetus/Newborn Infant</b> <a href="http://classic.pediatrics.aappublications.org/cgi/collection/fetus:newborn_infant_sub">http://classic.pediatrics.aappublications.org/cgi/collection/fetus:newborn_infant_sub</a> <b>Infectious Disease</b> <a href="http://classic.pediatrics.aappublications.org/cgi/collection/infectious_diseases_sub">http://classic.pediatrics.aappublications.org/cgi/collection/infectious_diseases_sub</a>
<b>Permissions &amp; Licensing</b>	Information about reproducing this article in parts (figures, tables) or in its entirety can be found online at: <a href="https://shop.aap.org/licensing-permissions/">https://shop.aap.org/licensing-permissions/</a>
<b>Reprints</b>	Information about ordering reprints can be found online: <a href="http://classic.pediatrics.aappublications.org/content/reprints">http://classic.pediatrics.aappublications.org/content/reprints</a>

Pediatrics is the official journal of the American Academy of Pediatrics. A monthly publication, it has been published continuously since . Pediatrics is owned, published, and trademarked by the American Academy of Pediatrics, 141 Northwest Point Boulevard, Elk Grove Village, Illinois, 60007. Copyright © 2013 by the American Academy of Pediatrics. All rights reserved. Print ISSN: .

American Academy of Pediatrics

DEDICATED TO THE HEALTH OF ALL CHILDREN™





# PEDIATRICS®

OFFICIAL JOURNAL OF THE AMERICAN ACADEMY OF PEDIATRICS

## **Guidance on Management of Asymptomatic Neonates Born to Women With Active Genital Herpes Lesions**

David W. Kimberlin, Jill Baley, COMMITTEE ON INFECTIOUS DISEASES and  
COMMITTEE ON FETUS AND NEWBORN

*Pediatrics* 2013;131:e635

DOI: 10.1542/peds.2012-3216 originally published online January 28, 2013;

The online version of this article, along with updated information and services, is  
located on the World Wide Web at:

<http://pediatrics.aappublications.org/content/131/2/e635>

Pediatrics is the official journal of the American Academy of Pediatrics. A monthly publication, it has been published continuously since . Pediatrics is owned, published, and trademarked by the American Academy of Pediatrics, 141 Northwest Point Boulevard, Elk Grove Village, Illinois, 60007. Copyright © 2013 by the American Academy of Pediatrics. All rights reserved. Print ISSN: .

American Academy of Pediatrics

DEDICATED TO THE HEALTH OF ALL CHILDREN™

